

# GROSS ANATOMY OF THE LIGAMENTS OF FETLOCK JOINT IN DROMEDARY CAMEL

Jamal Nourinezhad, Yazan Mazaheri and Mahmood Khaksary Mahabady

Department of Anatomy and Embryology, Faculty of Veterinary Medicine, Shahid Chamran University, Ahvaz, Iran

## ABSTRACT

Gross anatomy of the fetlock joint of the seven male adult one-humped camels were studied. In present study, the tendinous middle interosseous muscle, interdigital intersesamoid and straight sesamoid ligaments were observed. However, there was no proximal interdigital ligament. In conclusion, we found that the gross anatomy of the ligaments in one-humped camel fetlock joint share remarkable similarities with horses, and certain differences, with bactrian camel and domestic ruminants.

**Key words:** Anatomy, dromedary camel, fetlock joint, ligament, metacarpo/metatarsophalangeal joint

It is conceivable that foot joint features of camel are the result of a natural selection process that favoured adaptation to locomotion. Camel has the ability of walking in sandy rough terrain for a long time because of its special musculoskeletal system in the limbs (Gahlot, 2000).

The fetlock joint is a composite joint and is formed by the trochlea of the cannon bone, proximal articular surface of the first phalanx, and 2 pairs of proximal sesamoid bones (Getty, 1975; Nickel *et al*, 1986; Dyce *et al*, 2010). The ligaments support the ruminant's fetlock joint consists of proximal interdigital, collateral ligaments as well as proximal, middle, and distal ligaments of proximal sesamoid bones. The middle interosseous muscle is functionally considered as proximal ligament of the proximal sesamoid in ruminants, the middle sesamoid ligaments comprise collateral, palmar sesamoid ligaments, and interdigital intersesamoidean ligaments. There are several distal sesamoid ligaments i.e., cruciate, oblique sesamoid ligaments, interdigital palangosesamoid ligaments in ruminants, and straight sesamoid ligaments (ligamentum sesamoideum rectum) in horses (Getty, 1975; Nickel *et al*, 1986; Dyce *et al*, 2010).

Extensive research revealed very brief descriptions presented regarding fetlock joint anatomy in dromedary camel (Kumar and Dhingra, 1988 and Gahlot, 2000) and in bactrian camel (Zhaoquan and Zhengming, 1999). In the available books, Grossman (1960) did not mention anything concerning camel fetlock joint. Anatomical structure of the camel fetlock joint was reported by Smuts and Bezuidenhout (1987).

In the clinical aspect, among foot joints of the camel various disorders concerning fetlock joint were reported by Singh and Gahlot (1997), Ramadan (1994) and Gahlot (2000). Singh and Gahlot (1997) found that the incidence of foot disorders in males is more than females. Better knowledge on morphology of the camel fetlock joint is essential to assess of unique characteristics of locomotion patterns and to understand the biomechanical consequences of the ligament injury.

Therefore, this study was aimed to elucidate the detailed gross anatomy of the fetlock joint of the male dromedary camel (*Camelus dromedarius*) with emphasis on ligaments.

## Materials and Methods

The fetlock joints of 7 male adult one-humped camels were used for this study. The specimens, without any external abnormality or pathology were obtained from the slaughter house and immediately identified (thoracic and pelvic limbs). The age of animals was estimated from their incisor teeth (Ramdan, 1994), and ranged between 6- 10 years. The live weight of the animals (340-640 kg) was determined by the carcass weight (170- 320 kg).

In order to prevent dehydration, specimens were wrapped in newspapers, covered in plastic bag, and were kept in a refrigerator. After skinning and stripping off all the fascia, the course of the ligaments was examined through gross dissection. The middle interosseous muscle and digital flexor tendons along with the cannon bone were cut into slices for topographical examination and photographs were

---

SEND REPRINT REQUEST TO JAMAL NOURINEZHAD email: [j.nourinezhad@scu.ac.ir](mailto:j.nourinezhad@scu.ac.ir)

taken. The anatomical terminology used conforms to the *Nomina Anatomica Veterinaria* (2005).

## Results

The results indicated that there were no differences between the metacarpophalangeal and metatarsophalangeal joints in all specimens with the exception of cross-section of the middle interosseous muscle.

There were 2 axial and abaxial collateral ligaments for each digit. The collateral ligaments extended from each side of the distal end of the cannon bone, to the abaxial surface of the proximal extremity of the first phalanx. Superficially, the abaxial collateral ligament merged with fibres of collateral sesamoid ligament and with the abaxial extensor band of the middle interosseous muscle (Fig 1).

There was no proximal interdigital ligament. In the thoracic limb, middle interosseous muscle was mainly composed of tendon fibres which arose from carpal palmar ligament, distal row of carpal bones and the palmar surface of the cannon bone and ran distally between the groove on the cannon bone and the flexor tendons. At the beginning, the ligament was wide but it became gradually thicker along passing on the groove of the cannon bone (Fig 2). The ligament was thicker and stronger at the lateral border than the medial border (Fig 5). In the proximal third of the cannon bone, it was a very strong broad and had short fibrous band. The accessory or check ligament of the deep digital flexor tendon was observed. It was dorsally in contact with the deep digital flexor tendon and related palmarly to the middle interosseous muscle. The ligament was broad at the beginning but it became narrower and thicker at the distal end (Fig 2).

Above the fetlock joint, middle interosseous muscle was divided into four branches i.e., lateral and medial branches, middle part, and connecting branch for the superficial flexor tendon (Fig 2).

Lateral and medial branches released 2 abaxial extensor tendons, which were inserted on abaxial sesamoid bones and crossed abaxial surface of the first phalanges obliquely to join the medial tendon of common digital extensor and lateral digital extensor tendon. These were augmented by fibres from the collateral ligaments and somewhat from collateral sesamoid ligaments (Fig 3).

The middle part divided into 2 branches for the axial proximal sesamoid bones. Each of these

branches again subdivided into three axial extensor tendons between intertrochlear notch, divided one or two short and one long strong tendons (Fig 4). Each two short tendons then diverged dorsally and obliquely across the axial surface of the respective first phalanges to unite with the deep surface of medial and lateral tendons of common digital extensor muscle on the third proximal part of first phalanx (Fig 4). Each long extensor tendons extended and attached to the corresponding short axial extensor tendons but ended near the pastern joint (Fig 4).

Above the fetlock joint, middle interosseous muscle also detached a strong broad or connecting branch from its palmar surface which bifurcated, and each branch united the superficial digital tendon near the fetlock joint and formed a sheath for the passage of the deep digital tendon (Fig 5).

Cross section of the different portions of the middle interosseous muscle demonstrated that the middle interosseous muscle was almost composed of 2 or 3 layers in forelimb, whereas there were somewhat distinct connective tissue membranes between layers of middle interosseous muscles in the hindlimb (Fig 6). Furthermore, cross section of the different portions of the middle interosseous muscle revealed it to be inseparable from superficial and deep digital flexor tendons in the forelimbs, while the interosseous muscle was clearly separable from those digital flexor tendons in hindlimbs.

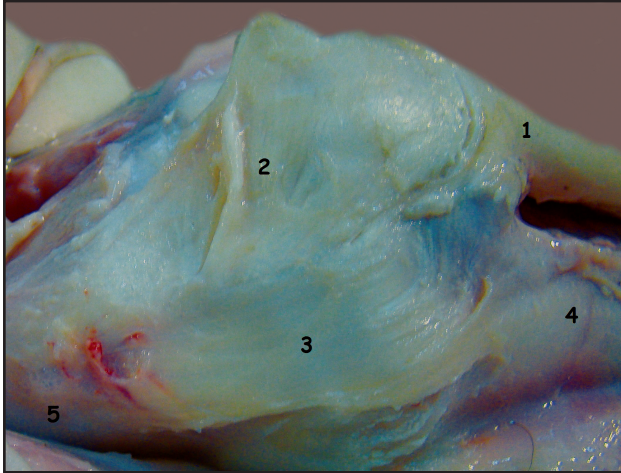
Medial and lateral palmar sesamoid ligaments were found one to each digit which connected the pair of the proximal sesamoid bones (Fig 7).

There was one collateral sesamoid ligament for each digit, which connected the abaxial proximal sesamoid with proximal end of the first phalanx and the distal end of the cannon bone. These were partly covered and augmented by the fibres of abaxial extensor tendons of the middle interosseous muscle and the collateral ligaments (Fig 1). At the intertrochlear notch, they covered the axial collateral sesamoid ligaments (Fig 3).

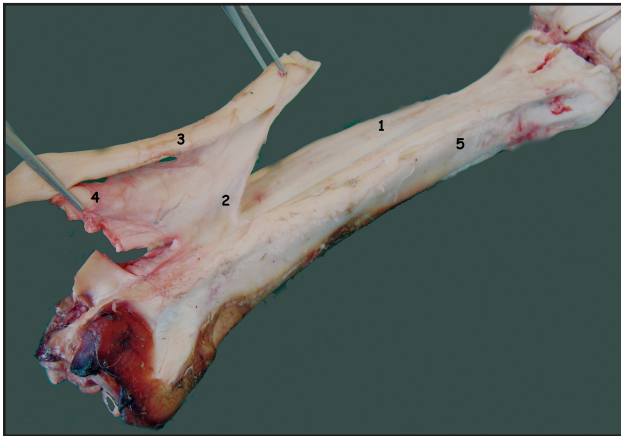
There was one stout interdigital intersesamoid ligaments which filled the space between proximal parts of 2 axial sesamoid bones (Fig 7).

There were no interdigital phalangosesamoid ligaments.

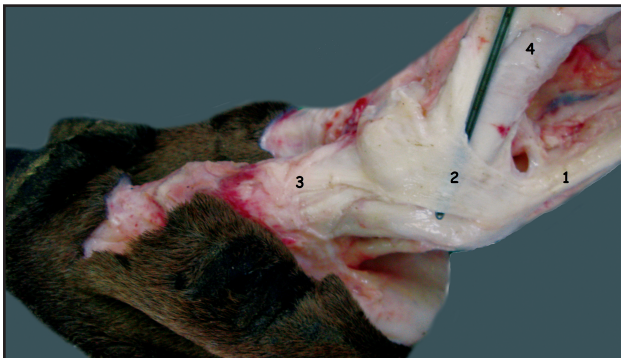
There was one oblique sesamoid ligament to each digit, which extended from the distal and palmar surfaces of the abaxial proximal sesamoids to the proximal extremity of first phalanx. It was



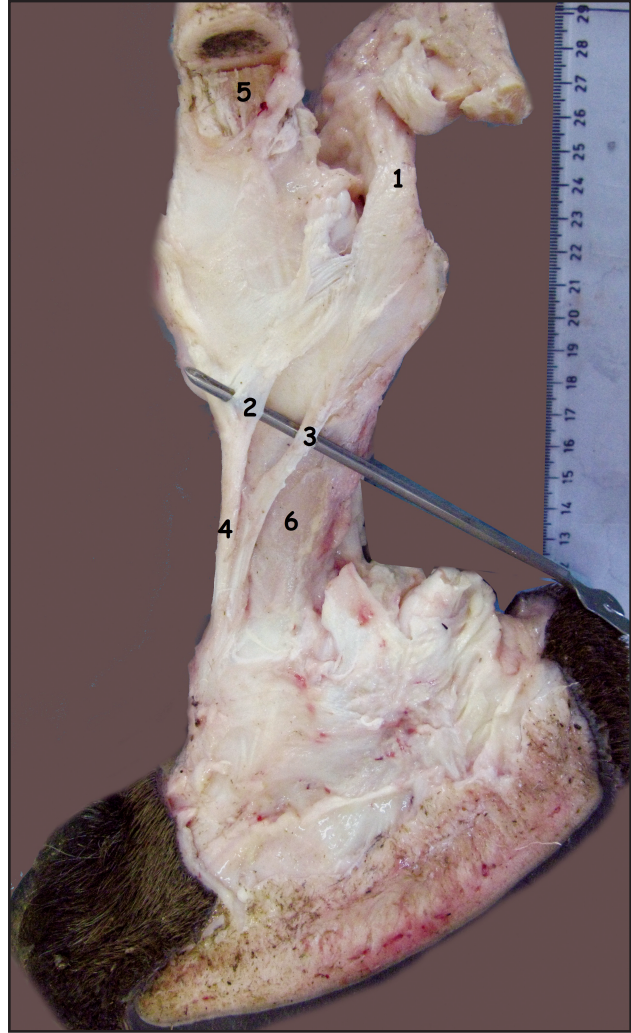
**Fig 1.** Lateral view of the the fetlock joint showing associated ligaments and structures. 1, middle interosseous muscle; 2, collateral sesamoid ligament; 3, collateral ligament; 4, cannon bone; 5, proximal phalanx.



**Fig 2.** Caudolateral view of the cannon bone showing associated middle interosseous muscle and structures. 1, middle interosseous muscle; 2, accessory(check) ligament; 3, superficial digital flexor tendon; 4, deep digital flexor tendon; 5, cannon bone.



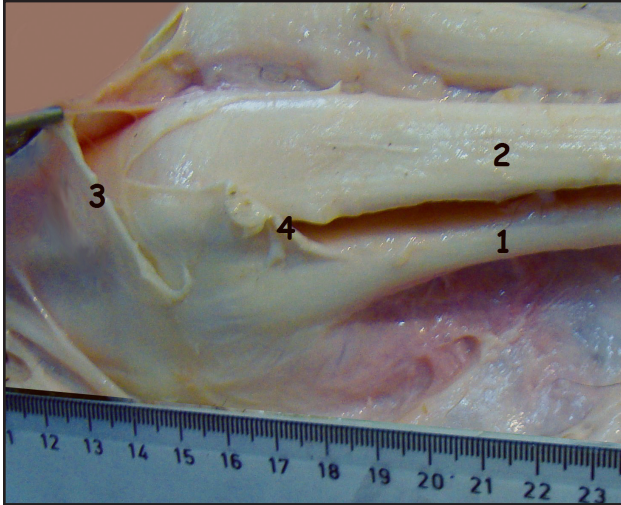
**Fig 3.** Lateral view of the the fetlock joint showing associated ligaments and structures. 1, middle interosseous muscle; 2, abaxial extensor branch; 3, lateral digital extensor tendon; 4, cannon bone.



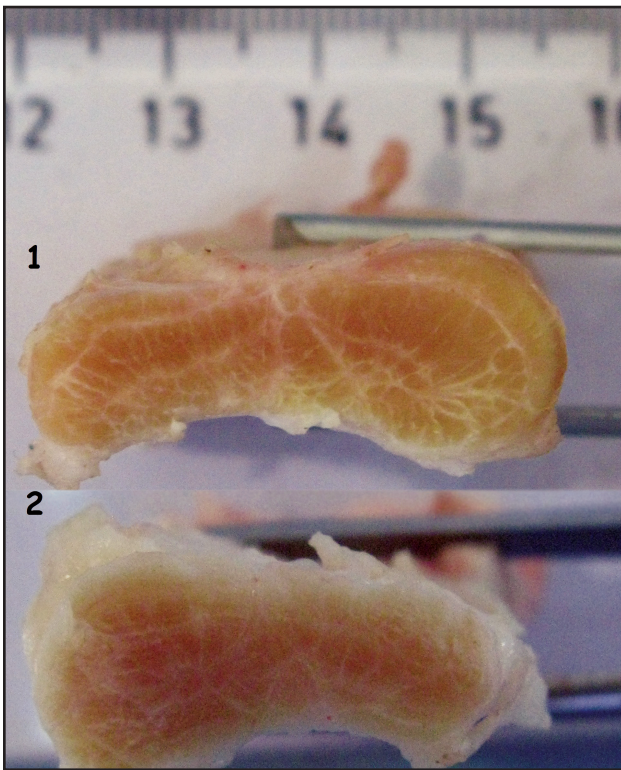
**Fig 4.** Medial view of the the fetlock joint showing associated ligaments and structures. 1, middle interosseous muscle; 2, short axial extensor branch; 3, long axial extensor branches; 4, common digital extensor tendons; 5, cannon bone; 6, proximal phalanx.

a flat band and somewhat wider proximally than distally. The ligament was located on either side of the straight sesamoid ligament but somewhat difficult proximally and distally to separate from each other. Its proximal portion partly merged with the fibres of collateral sesamoid ligament and collateral ligaments (Fig 7).

There was one straight sesamoid ligament to each digit which originated from the base of the sesamoid bones and was inserted to the palmar surface of the first phalanx. The ligament was stronger and more easily delineated than other distal sesamoid ligaments. The ligament had consistently a considerable thickness and width through out its course and was composed of two layers. The superficial layer was thicker and stronger which



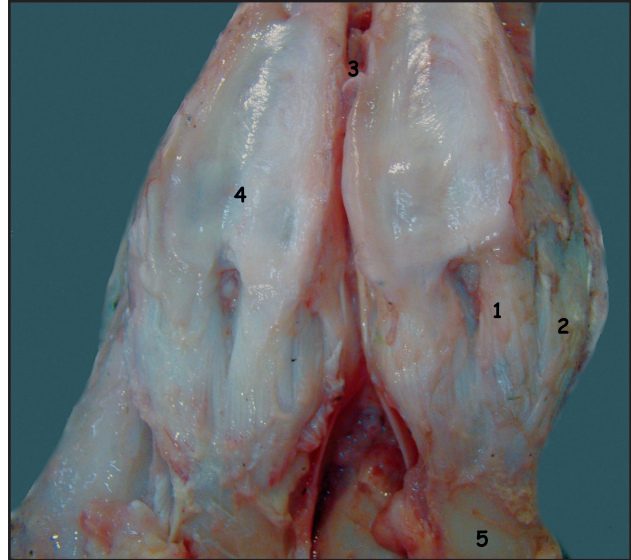
**Fig 5.** Lateral view of the fetlock joint showing associated ligaments and structures. 1, middle interosseous muscle; 2, superficial digital flexor tendon; 3, flexor retinaculum; 4- connecting branch to the superficial flexor tendon.



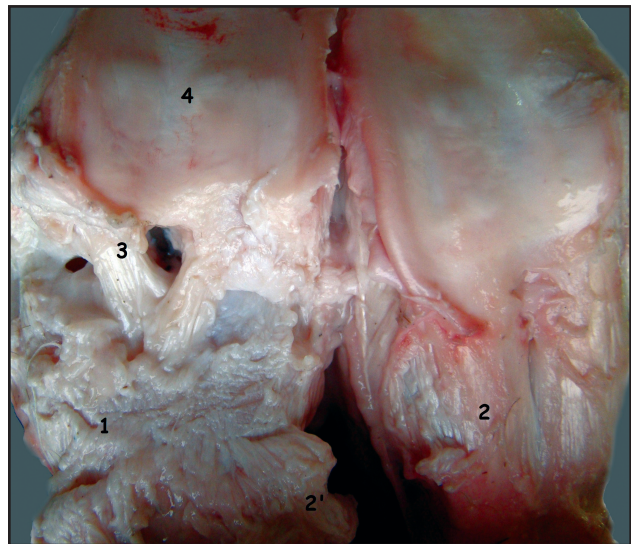**Fig 6.** Cross section of third proximal of middle interosseous muscle showing the structure have more layers in hindlimb. 1, right forelimb; 2, left hind limb.

connected to middle portion of the palmer surface of the first phalanx. The deep layer was thinner and attached to trigone on the palmar surface of the first phalanx (Fig 8).

There were 2 cruciate sesamoid ligaments to each digit, which ran from the base of each proximal



**Fig 7.** Palmar view of the fetlock joint showing associated ligaments and structures. 1, straight sesamoid ligament; 2, oblique sesamoid ligament; 3, interdigital intersesamoid ligament; 4, palmar sesamoid ligament; 5, proximal phalanx.



**Fig 8.** Palmar view of the fetlock joint showing associated ligaments and structures. 1, deep part of straight sesamoid ligament; 2 and 2', superficial part of straight sesamoid ligament; 3, cruciate sesamoid ligament; 4, palmar sesamoid ligament.

sesamoid to the palmar surface of the first phalanx. Only, the distal part of the ligaments crossed each other distinctly. The ligament was short and somewhat flat and was located completely under the straight sesamoid ligament (Fig 8).

### Discussion

In the present study, the collateral ligaments had only one layer. This result is in agreement with

previous findings reported by Getty (1975) and Nickel *et al* (1986) in ruminant as well as Smuts and Bezuidenhout (1987) in dromedary camel, while abaxial collateral ligaments of bactrian camel (Zhaoquan and Zhengming,1999) and collateral ligament of horse (Getty, 1975) consisted of 2 layers.

Concerning the proximal interdigital ligament, among the studies, Zhaoquan and Zhengming (1999) in bactrian camel, Getty (1975) and Nickel *et al* (1986) in small ruminants pointed out that the ligament is absent while it is said to be present in large ruminants (Getty, 1975 and Nickel *et al*, 1986). In addition, Smuts and Bezuidenhout (1987) and Kumar and Dhingra (1988) did not mention anything regarding the existence of the ligament in one-humped camels. In the current study, there was no proximal interdigital ligament. One possible explanation is that this feature may contribute to allow for the divergence of the paired digits.

In one humped camels, Kumar and Dhingra (1988) asserted that the middle interosseous muscle of the forelimb have superficial and deep portions. However, Smuts and Bezuidenhout (1987) in one-humped camels, Getty (1975), and Nickel *et al* (1986) in ruminant showed middle interosseous muscle has only one layer. In the present study, the middle interosseous muscle was found to consist of more than one-layer.

No data could found related to the branches of middle interosseous muscle in one humped camels. In our observations, the middle interosseous muscle was mainly composed of tendon fibres. Such characteristic has been described in dromedary camel (Smuts and Bezuidenhout, 1987 and Gahlot, 2000) and in horses (Getty, 1975 and Nickel *et al*, 1986). However, middle interosseous muscle consists of both fleshy and tendinous tissues in ruminants (Getty, 1975 and Nickel *et al*, 1986)

The available review of literature did not reveal the anatomical presence of accessory (check) ligament in camel. In our study, the accessory ligament of the deep digital flexor tendon was present. Getty (1975) and Nickel *et al* (1986) reported that except in horse, there is no accessory ligament of the deep digital flexor tendon in other domestic animals.

A literature search did not bring up any data or publications on the existence of the middle interosseous muscle giving off branches to the superficial digital flexor tendon in bactrian and dromedary camels. Getty (1975) and Nickel *et al* (1986) showed that there is no slips result from middle

interosseous muscle to the superficial digital flexor tendon in horse, while connecting branch to the superficial digital flexor tendon existed in cattle. The finding in cattle is consistent with our results.

In this study, the abaxial extensor tendons of the middle interosseous muscle was found. This finding accorded with the result of previous descriptions in the ruminants and horses (Getty, 1975 and Nickel *et al*, 1986). However, it was reported only in one data that there were no branches to the extensor tendons from middle interosseous muscle in one-humped camels (Smuts and Bezuidenhout, 1987).

Surprisingly, our study showed that there was one long extra axial extensor tendon, derived from the middle interosseous muscle which inserted to tendons of common digital extensor near pastern joint, which was not recorded in previous findings in the ruminants (Getty, 1975 and Nickel *et al*, 1986). However, it seems that the tendon is corresponding with the slender fibrous band for pastern joint in one-humped camels, which was mentioned by Smuts and Bezuidenhout (1987).

Regarding middle sesamoid ligaments, all ligaments of this group were found in this research, is in agreement with previous literatures reported in the ruminants and horse (Getty, 1975 and Nickel *et al*, 1986) as well as in one-humped camel (Kumar and Dhingra, 1988; Smuts and Bezuidenhout, 1987). However, there was no connection between the sesamoids of the lateral and medial joint in one-humped camels (Smuts and Bezuidenhout, 1987). This is in disagreement with present study.

In the present investigation, we did not find interdigital phalangosesamoid ligaments. This finding corresponds with the results of previous investigations in one-humped camels (Smuts and Bezuidenhout, 1987 and Kumar and Dhingra, 1988) and in bactrian camels (Zhaoquan and Zhengming, 1999). On the contrary, the presence of interdigital phalangosesamoid ligaments was denoted in ruminants (Getty, 1975 and Nickel *et al*, 1986).

The existence of straight sesamoid ligament was indicated in one humped camels (Smuts and Bezuidenhout, 1987) and in horse (Getty, 1975 and Nickel *et al*, 1986). The ligament was not described in bactrian camels (Zhaoquan and Zhengming, 1999) and in domestic ruminants (Getty, 1975 and Nickel *et al*, 1986). In the present study, there were straight sesamoid ligaments. However, it should be noticed that in horses, straight sesamoid ligament was attached to proximal end of the second phalanx (Getty, 1975) or the first phalanx (Nickel *et al*, 1986)

while, we found straight sesamoid ligament ended to the first phalanx. We conclude that insertion of straight sesamoid ligament in one-humped camels, is in agreement with the results of previous findings in horse (Nickel *et al*, 1986) and in one-humped camels (Smuts and Bezuidenhout, 1987).

There is no data in the literature concerning the straight sesamoid ligament being composed of two layers in bactrian and dromedary camels or even in domestic animals. Present result denoted that the straight sesamoid ligament consisted of 2 layers.

Present findings regarding the presence of oblique and cruciate sesamoid ligaments, accord with the results of previous studies in domestic animals (Getty, 1975 and Nickel *et al*, 1986) and in one-humped camels (Smuts and Bezuidenhout, 1987).

In conclusion, it seems that the gross anatomy of the ligaments in one-humped camel fetlock joints share remarkable similarities with horses, and certain differences with bactrian camels and domestic ruminants.

### Acknowledgements

The skillful help of Mr. R. Fathi and E. Sadeghi are gratefully acknowledged. We also thank Mr. Dr. Daram for editing the manuscript. The Shahid Chamran University supported this study.

### References

Dyce KM, Sack WO and Wensing CJG (2000). Textbook of Veterinary Anatomy. 4th Edn. W B Saunders Co. Philadelphia. pp 585-586, 736-737.

- Getty R (1975). Equine syndesmology, ruminant syndesmology. In: Sisson and Grossman's the Anatomy of the Domestic Animals, 5 th Edn. Vol 1, W. B. Saunders Co. Philadelphia. pp 350-375, 787-790.
- Gahlot TK (2000). Surgery of the dromedary camel, In: Selected Topics on Camelids. The Camelid Publishers, India. pp 409-423.
- Grossman JD (1960). A student guide to anatomy of the camel. Education series No 5, Indian Council of Agricultural Research, New Dehli. pp 21.
- Nomina Anatomica Veterinaria (2005). World Association of Veterinary Anatomists, 5th Edn, Published by the Editorial Committee. Hanover, Colombia, Gent, Sapporo.
- Kumar S and Dhingra D (1988). Osteoarthology of foot joints in camel. Indian Journal of Animal Sciences 58(1):85-87.
- Nickel R, Schummer A and Seiferle E (1986). The Anatomy of the Domestic Animals, the Locomotor System of the Domestic Mammals. Verlag Paul Parey, Berlin, Hamburg. pp 169-231.
- Ramdan RO (1994). Surgery and Radiology of the Dromedary Camel. 1<sup>st</sup> Edn. Al-Jawad Printing Press. King Faisal University, Saudi Arabia. pp 24-36.
- Singh G and Gahlot TK (1997). Foot disorders in camels (*Camelus dromedarius*). Journal of Camel Practice and Research 4(2):145-154.
- Smuts MS and Bezuidenhout AJ (1987). The joints and ligaments. In: The Anatomy of Dromedary. Clarendon Press, Oxford. pp 48-58.
- Zhaoquan M and Zhengming X (1999). Anatomical structure of the metatarsophalangeal joints (articulations metatarsophalangeae) in Bactrian camels (*Camelus bactrianus*). Chinese Journal of Veterinary Sciences 19(1):61-64.